



Intervertebral disc disease (IVDD): Instructions for radiography according to the Swedish Kennel Club protocol

By: Anu Lappalainen

General instructions:

- The dog must be sedated for the radiography and the microchip must be checked.
- The radiographs must be marked permanently (e.g. lead tape) with the dog's registration number or microchip number and the date of the radiography.

Radiographs:

In all images the spine must be parallel to the table without rotation of the spine. Use foam rubber supports (Figure 1). **All disc spaces must be clearly visible.**

At least 5 radiographs are needed:

- 1) Lateral cervical spine (**C1-C7**) (Figure 2). The front limbs are pulled back. Centering in the midcervical spine.
- 2) Lateral cervico-thoracic junction (Figure 3). Centering int the C-T junction.
- 3) Lateral thoracic spine = **C7 – L1** covered preferably in one image (Figure 4).
- 4) Lateral thoracic-lumbar junction (Figure 5). Centering int the T-L junction.
- 5) Lateral lumbar spine = **T13 – Cd1** covered preferably in one image (Figure 6). If this is not possible,two radiographs are made (T13 – L7 and L5 – Cd 1). The cranial border of the iliac bones can beused as a land mark for identification of the vertebrae.



Figure 1 Positioning

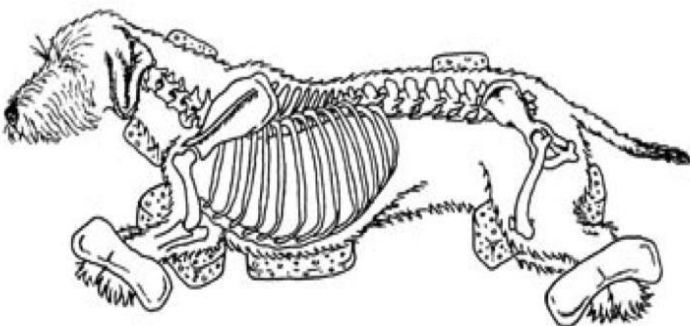
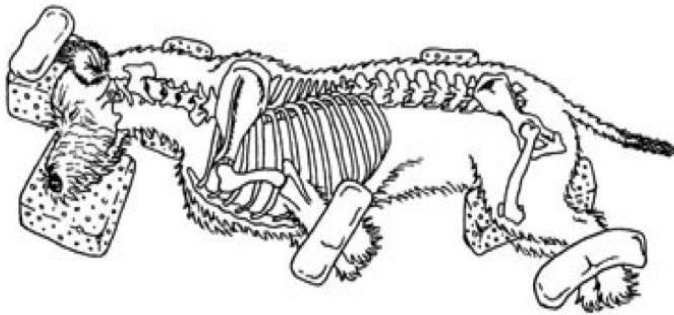
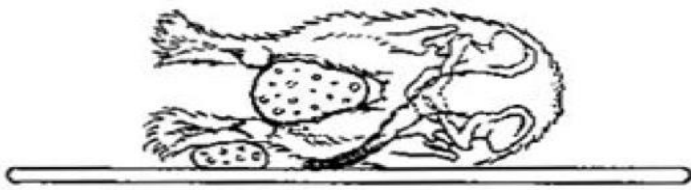
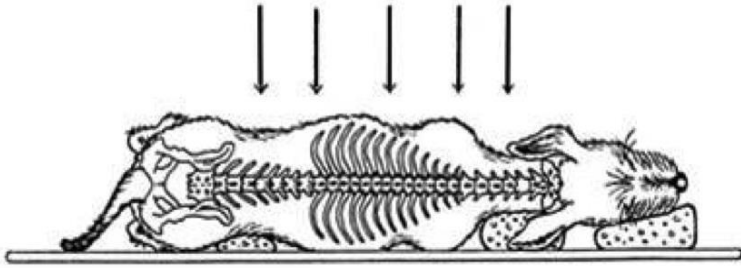




Figure 2 Cervical spine

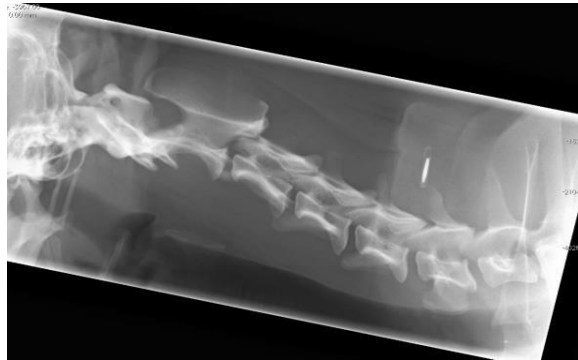


Figure 3 C-T junction

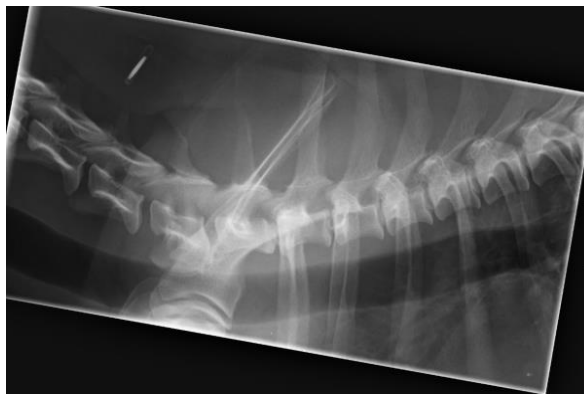


Figure 4 Thoracic spine

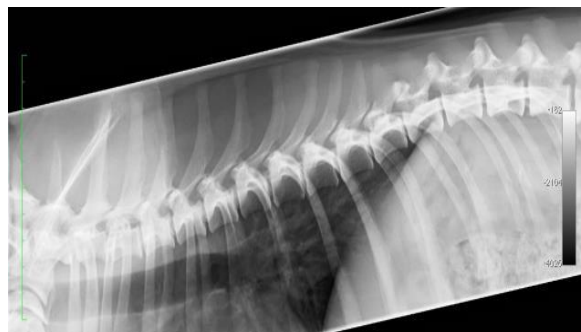
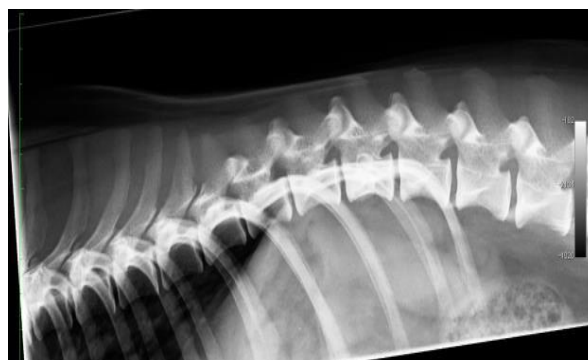

Figure 5 T – L junction





SVENSKA KENNELKLUBBEN

HUNDÄGARNAS RIKSORGANISATION

Figure 6 Lumbar spine

